



Glenohumeral instability and coracoid fracture nonunion corrected without coracoid transfer or nonunion takedown

John G. Skedros, MD^{a,b,c,*}, Chad S. Mears, BS^b, Colton M. Phippen^b

^aThe University of Utah Department of Orthopaedic Surgery, Salt Lake City, UT, USA

^bUtah Orthopaedic Specialists, Salt Lake City, UT, USA

^cIntermountain Medical Center, Salt Lake City, UT, USA

Anterior shoulder dislocations are commonly associated with humeral greater tuberosity fractures (~16% of cases), which include Hill-Sachs lesions.¹⁹ The second most common fracture associated with an anterior shoulder dislocation is a fracture of the anterior glenoid (i.e., bony Bankart lesion). By comparison, a coracoid fracture occurring in association with an anterior shoulder dislocation is uncommon.¹⁶ In fact, fractures of the coracoid process are generally very uncommon, representing only 2% to 5% of all fractures of the scapula, including those not associated with a shoulder dislocation.^{5,9,19} Although symptomatic nonunion is a known complication of coracoid fractures,⁷ the majority of isolated coracoid fractures with minimal or no displacement heal with 6 weeks of immobilization without surgery.^{3,6}

A very small number of anterior shoulder dislocations with coracoid fractures lead to chronic problems. This includes chronic glenohumeral instability with a coracoid fracture nonunion. We report a case of a shoulder injury that resulted in chronic glenohumeral instability and a basilar coracoid fracture nonunion. These problems were surgically corrected with a conventional open capsular shift and surgical fixation of the coracoid nonunion without takedown of the nonunion site or transfer of the coracoid.

This is a unique case because in a majority of reported cases of the association of these 2 problems, the nonunion was mobilized and transferred to the region of the glenoid neck (i.e., Bristow-Latarjet procedure) or involved other perturbation of the subscapularis in the vicinity of the glenoid neck.^{1,7,15,18,20} Our patient was able to return to his work in heavy manual labor as an automobile mechanic and was very satisfied with his final result.

Case report

The patient is a 50-year-old right-hand dominant man who presented to our clinic with a chief complaint of right shoulder pain and instability (i.e., a “feeling that the shoulder almost dislocates with reaching and lifting”). This was caused by a work-related injury that occurred 15 months earlier. At the time, he was employed as an automobile mechanic, which included heavy manual labor (e.g., engine and transmission installation), and was working on the transmission of a motor home vehicle when the motor home fell off the jack and pinned him beneath it. The patient reported that his shoulder had dislocated and then spontaneously relocated as he was extracted from beneath the vehicle. Radiographs taken that day showed that the shoulder joint was not dislocated and a fracture was not detected. Magnetic resonance (MR) scans done 6 weeks after the trauma showed a nondisplaced basilar coracoid fracture; this was a type III fracture in terms of the classification of Eyres et al.⁶

He reported that his shoulder felt unstable since the incident. He also described moderate pain with lifting and reaching. These symptoms did not subside with supervised physical therapy and anti-inflammatory medications. At the first visit to our clinic, his

Ethical Review Committee approval: Each author certifies that his institution has approved the reporting of this case, that all investigations were conducted in conformity with ethical principles of research, and that informed consent for participation in the study was obtained.

*Reprint requests: John G. Skedros, MD, Utah Orthopaedic Specialists, 5323 South Woodrow St, Ste 200, Salt Lake City, UT 84107, USA.

E-mail address: jskedrosmd@uosmd.com (J.G. Skedros).

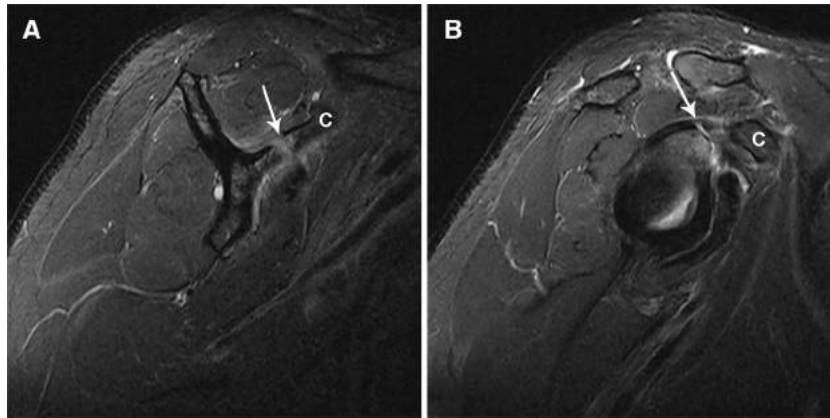


Figure 1 Magnetic resonance images of the patient's right shoulder showing the coracoid (C) fracture nonunion (*arrows*). These scans were obtained 1 year after the trauma.

Disabilities of the Arm, Shoulder and Hand (DASH) score was 73 (best = 0, worst = 100).^{11,21} The patient had no shoulder dysfunction for many years before this work-related injury. However, nearly 30 years earlier, he had a midshaft right clavicle fracture and a grade 3 acromioclavicular separation. Both of these injuries healed without surgery and were not associated with subsequent problems. There were no prior right shoulder surgeries.

Our first physical examination of the patient's right shoulder (15 months after the trauma) showed a moderate sulcus sign and positive apprehension and relocation maneuvers. He also had exquisite pain with direct manual compression over the coracoid. Repeated MR scans, done 1 year after the trauma, showed that the nondisplaced coracoid fracture had not healed (*Fig. 1*). A patulous anterior capsular area consistent with ligament tearing was also seen in these MR scans. Radiographs taken at his first visit to our clinic also showed the coracoid fracture nonunion (*Fig. 2, A*).

The surgical plan was as follows. If the nonunion was found to be highly mobile, the plan was to perform a Bristow-Latarjet type of procedure similar to the treatment of Robinson et al¹⁸ for patients with coracoid fracture nonunions and shoulder instability. However, intraoperatively, it was found that the coracoid showed only very minor gross motion. Furthermore, the coracoacromial and coracoclavicular ligaments were intact. Consequently, the nonunion was treated with cortical "petalling" with a 0.25-inch (6.35-mm) osteotome, which was done circumferentially across the nonunion site and the regions proximal and distal to it.¹² Demineralized bone matrix paste (Grafton; Osteotech Inc, Eatontown, NJ, USA) was applied on the petalled bone surface, which was essentially a modified onlay graft (without takedown of the nonunion) as described by Phemister.¹⁷ A 3.5-mm lag screw was then placed across the fracture site to provide stability and compression.^{2,6,8,16} The glenohumeral instability was treated with a conventional open anterior capsular shift procedure.¹⁴

The nonunion healed (*Fig. 2, B*), and the stability of the shoulder was restored. At 10 months after operation, the patient had returned to full-time work as an automobile mechanic. At 18 months after the operation, he stated that he was very satisfied with his final result, and his final DASH score was 8 (73 before the operation).

Discussion

In a series of 67 consecutive patients with fractures of the coracoid process, Ogawa et al¹⁶ reported that the most common associated lesion was an acromioclavicular dislocation (39 patients, 58% of the cohort). The following lesions were also reported in descending order of prevalence in that cohort: fracture of the superior scapular margin (24 patients, 36%); laceration or abrasion over the deltoid (15 patients, 22%); clavicle fracture (14 patients, 21%); acromion fracture (13 patients, 19%); scapula spine fracture (5 patients, 7%); rotator cuff tear and anterior shoulder dislocation (3 patients each); and glenoid rim and proximal humerus fractures (2 patients each). In this perspective, our patient's case is very uncommon and is even more so because of the association of chronic glenohumeral instability and a coracoid fracture nonunion. It is also unique in the context of reports in the literature because (1) the coracoid distal to the nonunion site was not transferred to the glenoid rim, (2) the coracoid nonunion healed with cortical petalling without takedown of the nonunion site, and (3) the coexisting shoulder instability was treated with a conventional open capsular shift procedure. Although it is possible that the coracoid nonunion might have healed by stabilizing the glenohumeral joint without use of the lag screw or cortical petalling,⁴ there is literature supporting the surgeon's judgment that union would most likely be achieved if these additional measures were taken, especially because the patient worked in heavy manual labor.^{7,8,10}

There are several case reports of patients who have had coracoid fracture nonunions that were treated with procedures similar to the conventional Bristow or Latarjet. For example, in one of the few cases that we located that resemble the injuries in our patient (but no nonunion), Subramanian et al²² reported a case of a 64-year-old man who had trauma that caused an acute coracoid fracture and anterior glenohumeral instability. These injuries were treated acutely with open reduction and internal fixation of

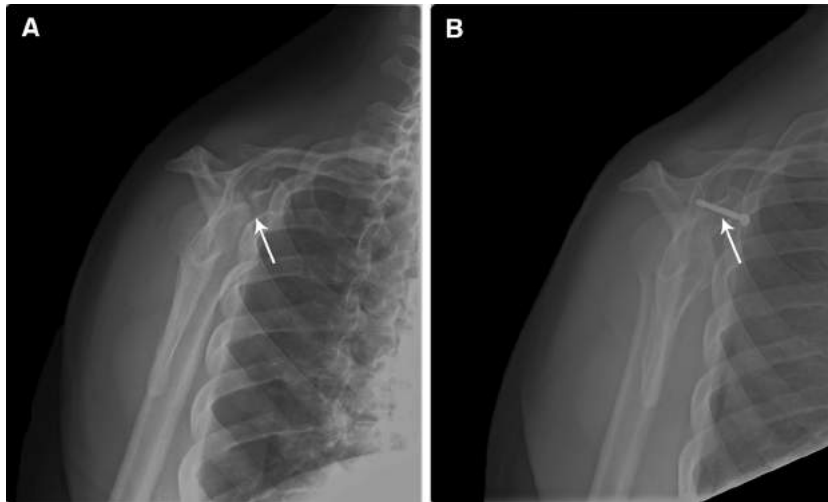


Figure 2 Radiographs showing the nonunion site (A, arrow) before operation and the healed nonunion site (B, arrow) with the screw at 6 months after operation.

the fracture and repairs of the torn glenohumeral capsule ligaments and subscapularis tendon. In another case more similar to ours, Källick et al¹³ described a 34-year-old man who had the coexistence of glenohumeral instability and a coracoid fracture pseudarthrosis. These were treated surgically with a Bankart repair and with reconstruction of the coracoid nonunion with iliac crest bone graft and a titanium screw supplemented with a polydioxanone cord (specific details of how the cord was used were not provided).

Robinson et al¹⁹ investigated the association between coracoid fracture nonunions and glenohumeral instability in patients with seizure disorders. Their report described 6 shoulders in 5 patients (mean age, 26 years; range, 24–30 years). Surgical treatment in all patients included an open osseous reconstructive procedure (e.g., coracoid nonunion takedown and transfer of the distal coracoid to the anterior glenoid rim). The type of procedure that was done was based on the location of the nonunion. In the 4 shoulders with the coracoid nonunion located at its “elbow,” a Bristow-Latarjet procedure was performed. In the 2 shoulders in which the nonunion was more toward the distal aspect of the coracoid, an Eden-Hybbinette procedure was performed. Allagui et al¹ also described a 29-year-old man with recurrent anterior shoulder dislocations and pseudarthrosis of the horizontal part of the coracoid process. This was also treated with the Latarjet procedure.

Saragaglia et al²⁰ described 3 patients (ages 18, 31, and 46 years) with anterior instability of the shoulder associated with a fracture of the “horizontal part” of the coracoid process. Unlike our patient, all of their patients had reconstruction with the Latarjet procedure. Therefore, the fractures they reported were more toward the distal end of the coracoid compared with the basilar fracture in our patient. Their cases included a patient with recurrent anterior shoulder dislocations associated with a fracture (not a nonunion) of the horizontal part of the coracoid process, a patient with a pseudarthrosis of the coracoid process associated with a

fracture of the anterior inferior aspect of the glenoid causing shoulder instability, and a patient with a recurrent shoulder dislocation associated with a pseudarthrosis of the coracoid that was detected intraoperatively. Lal et al¹⁵ also described a 48-year-old man with recurrent anterior shoulder dislocations who had a distal coracoid fracture that was discovered intraoperatively. In that case, the fragment was “routed with the attached short head of biceps and coracobrachialis through the lower one third of the subscapularis, before homing it and fixing it to the proximal coracoid fragment.”

Garcia-Elias and Salo⁷ described a 53-year-old man with a shoulder dislocation and coracoid fracture. Although the shoulder became stable without surgery, the coracoid fracture did not heal and remained symptomatic. This was treated surgically by removing the distal fragment of the coracoid and reattaching the tendons of the biceps (short head), coracobrachialis, and pectoralis minor muscles to the proximal end of the remaining coracoid. This procedure was successful in alleviating the patient’s symptoms.

Conclusion

Our case is unique because the chronic glenohumeral instability and a basilar coracoid fracture nonunion were successfully corrected, respectively, with a conventional open capsular shift and fixation of the coracoid nonunion with cortical petalling and onlay graft, but without takedown of the nonunion site or transfer of the coracoid.

Disclaimer

The authors, their immediate families, and any research foundation with which they are affiliated did not

receive any financial payments or other benefits from any commercial entity related to the subject of this article.

References

- Allagui M, Aloui I, Hammouda I, Koubaa M, Abbadi A, Hamdi MF, et al. [Pseudarthrosis of the coracoid process after dislocation of the shoulder]. *Chir Main* 2009;28:363-6. <http://dx.doi.org/10.1016/j.main.2009.08.013>
- Anavian J, Wijdicks CA, Schroder LK, Vang S, Cole PA. Surgery for scapula process fractures: good outcome in 26 patients. *Acta Orthop* 2009;80:344-50. <http://dx.doi.org/10.3109/17453670903025394>
- Butters KP. Fractures and dislocations of the scapula. In: Rockwood CA Jr, Green DP, Bucholz RW, et al., editors. *Fractures in adults*. Philadelphia: Lippincott-Raven; 1996.
- DeRosa GP, Kettelkamp DB. Fracture of the coracoid process of the scapula: case report. *J Bone Joint Surg Am* 1977;59:696-7.
- Émond M, Le Sage N, Lavoie A, Rochette L. Clinical factors predicting fractures associated with an anterior shoulder dislocation. *Acad Emerg Med* 2004;11:853-8. <http://dx.doi.org/10.1197/j.aem.2004.03.009>
- Eyres KS, Brooks A, Stanley D. Fractures of the coracoid process. *J Bone Joint Surg Br* 1995;77:425-8.
- Garcia-Elias M, Salo JM. Non-union of a fractured coracoid process after dislocation of the shoulder. A case report. *J Bone Joint Surg Br* 1985;67:722-3.
- Goss TP. The scapula: coracoid, acromial, and avulsion fractures. *Am J Orthop (Belle Mead NJ)* 1996;25:106-15.
- Goss TP, Owens BD. Fractures of the scapula. In: Rockwood CA Jr, Matsen FA III, Wirth MA, et al., editors. *The shoulder*. Philadelphia: Saunders Elsevier; 2009. p. 333-80.
- Guttentag IJ, Reichtine GR. Fractures of the scapula. A review of the literature. *Orthop Rev* 1988;17:147-58.
- Hudak PL, Amadio PC, Bombardier C. Development of an upper extremity outcome measure: the DASH (disabilities of the arm, shoulder and hand) [corrected]. The Upper Extremity Collaborative Group (UECG). *Am J Ind Med* 1996;29:602-8.
- Jarry L, Uhthoff HK. Activation of osteogenesis by the "petal" technique. *J Bone Joint Surg Br* 1960;42:126-36.
- Källicke T, Andereya S, Gekle J, Muller EJ, Muhr G. [Coracoid pseudarthrosis caused by anterior shoulder dislocation with concomitant coracoid fracture]. *Unfallchirurg* 2002;105:843-4. <http://dx.doi.org/10.1007/s00113-002-0427-2>
- Kvitne RS, Jobe FW. The diagnosis and treatment of anterior instability in the throwing athlete. *Clin Orthop Relat Res* 1993;107-23.
- Lal H, Bansal P, Sabharwal VK, Mawia L, Mittal D. Recurrent shoulder dislocations secondary to coracoid process fracture: a case report. *J Orthop Surg (Hong Kong)* 2012;20:121-5.
- Ogawa K, Yoshida A, Takahashi M, Ui M. Fractures of the coracoid process. *J Bone Joint Surg Br* 1997;79:17-9.
- Phemister DB. Treatment of ununited fractures by onlay bone grafts without screw or tie fixation and without breaking down of the fibrous union. *J Bone Joint Surg Am* 1947;29:946-60.
- Robinson CM, Al-Hourani K, Malley TS, Murray IR. Anterior shoulder instability associated with coracoid nonunion in patients with a seizure disorder. *J Bone Joint Surg Am* 2012;94:e40. <http://dx.doi.org/10.2106/JBJS.K.00188>
- Robinson CM, Shur N, Sharpe T, Ray A, Murray IR. Injuries associated with traumatic anterior glenohumeral dislocations. *J Bone Joint Surg Am* 2012;94:18-26. <http://dx.doi.org/10.2106/JBJS.J.01795>
- Saragaglia D, Picard F, Gerard P, Tourne Y, Leroy JM. [Anterior instability of the shoulder associated with fracture of the coracoid process. Apropos of 3 cases]. *Rev Chir Orthop Reparatrice Appar Mot* 1994;80:651-5.
- SooHoo NF, McDonald AP, Seiler JG 3rd, McGillivray GR. Evaluation of the construct validity of the DASH questionnaire by correlation to the SF-36. *J Hand Surg Am* 2002;27:537-41. <http://dx.doi.org/10.1053/jhsu.2002.32964>
- Subramanian AS, Khalik MA, Shah MM. Isolated fracture of the coracoid process associated with unstable shoulder. *ANZ J Surg* 2007;77:188-9. <http://dx.doi.org/10.1111/j.1445-2197.2006.04005.x>