

# Clinical Radiographic Projections of the Upper Humerus can Result in Substantial Errors When Quantifying the Deltoid Tuberosity Index, Cortical Index, and Other Morphological Characteristics: A Controlled Study in Cadaveric Humeri

Colton M. Phippen<sup>1</sup>, Tanner D. Langston<sup>1</sup>, Chad S. Mears<sup>1</sup>, Alex J. Drew<sup>1</sup>, Kent N. Bachus<sup>1</sup>, Mark T. Nielsen<sup>1</sup>, John G. Skedros<sup>1</sup>

<sup>1</sup>University of Utah, Salt Lake City, UT

Disclosures: No authors have any disclosures

**INTRODUCTION:** Anterior-posterior (AP) radiographs can be used for assessing bone quality and mass in the proximal humerus [1-4], and this information can be used for determining the most optimal method of fracture fixation [3,5]. Several studies have attempted to determine the most efficient method for making morphological-based preoperative measurements from clinical radiographs. Cortical index (CI) is the most common measurement and is calculated as the difference between the outer (OD) and inner diameters (ID) divided by the OD [(OD-ID)/OD] (lower CI values = weaker bone). The mean combined cortical index (OD-ID) is also a useful measure because it is, when compared to CI, a much stronger predictor of BMD and ultimate fracture load [1,3]. The most popular method for making these simple measurements is that of Tingart et al. (2003) [1]. The “Tingart method” is as follows: “The lateral and medial cortical thickness of the proximal humeral diaphysis was measured at two different levels. Level 1 was the most proximal level of the humeral diaphysis where the endosteal borders of the lateral and medial cortices were parallel to each other. Level 2 was 20 mm distal to level 1.” (Fig. 1) However, it has been argued that the Tingart method is limited because: (1) it relies on landmarks that can be obscured by fractures, and (2) there is a need for adjustment due to magnification errors and without a reference available can lead to inaccuracies in some cases [4]. In order to circumvent these shortcomings, Spross et al. (2015) [4] introduced the “deltoid tuberosity index” (DTI). The DTI is a quasi CI measured at a specific location that can be, so they claim, more reliably located than the aforementioned method of Tingart et al. Spross et al. measure the DTI at the location that is “as directly proximal to the deltoid tuberosity where the outer cortical borders become parallel”; the DTI is calculated “by dividing the outer cortical by the inner endosteal diameter at [that] level”. They found that the DTI was superior when compared to the Tingart method in terms of correlating with BMD of the proximal humerus measured using pQCT. They also concluded that the DTI is an accurate and efficient method when evaluating clinical AP radiographs of patients with fractured proximal humeri (i.e., internally rotated because of the use of a sling). However, in our studies of morphological measurements made from standard AP radiographs of cadaveric humeri [3], we have observed that the deltoid tuberosity is a highly unreliable landmark due to its variable presence and/or difficulty in visualizing it in the different angles of projection that are obtained in the clinical setting when evaluating proximal humerus fractures and in non-fracture cases. If our observations are correct, then it would be impossible to use this landmark as a reliable reference point for any of the aforementioned simple radiographic measures of cortical thickness and index. We used an idealized model (i.e., clinically relevant clinical projections of non-fractured cadaver bones) to test the hypothesis that the deltoid tuberosity is variably present and/or difficult to discern in many cases.

**METHODS:** Twenty fresh-frozen adult proximal humeri were obtained for this study (age range: 21-74); 13 males (ages: 22-74 years) and 7 females (ages: 21-65). The bones were manually dissected free of soft tissues prior to being digitally radiographed in five projections: (1) true anterior-posterior (i.e., each bone was externally rotated so to neutralize the natural retroversion of the humeral head) [6,7], (2) epicondyles oriented flat with respect to the horizontal (coronal) plane when viewing the bone from the distal end along its long axis (i.e., the epicondylar axis is in the coronal plane) [6], (3) 30° internally rotated from the orientation of #2, (4) 60° of internal rotation from the orientation of #2, and (5) 90° of internal rotation from the orientation of #2. The latter two projections simulated the range of internal rotation that a typically sized patient would have when their forearm is on their abdomen (as if they wore a sling). One investigator (the orthopaedic surgeon) oriented and radiographed the bones (JGS) as he had done in prior published studies [3,8] (GE Medical Systems; Siemens Model A101F). For each bone the beam was focused at 2 cm below the lower edge of the humeral head when fit to a circle [3]. The five observers that determined the location of the deltoid tuberosity included a graduate student, a biomechanical engineer who had written his thesis on humerus morphology, a board-certified orthopaedic surgeon, a board-certified radiologist, and a professor of human anatomy. All observers were trained in viewing proximal humeral radiographs. Using ImageJ the observers placed an arrow at the proximal aspect of the deltoid tuberosity (if it could be seen) on each of the radiographs (Figure 2). This was done on five separate sets of images (20 images/set), and the images were randomly arranged within each set. Each “set” of 20 images corresponded to one of the five radiographic projections. The observers were blinded to the hypothesis of the study and they were given instructions to read Spross et al. (2015) [4] and use their methods to indicate the upper edge of the deltoid tuberosity (as described above).

**RESULTS:** The results of three representative observers are shown in the data Table. The deltoid tuberosity could not be identified in these percentages of the 20 bones: (1) 18% of true AP view, (2) 23% of epicondyles flat view (epicondyles in the coronal plane), (3) 40% of 30° internally rotated view, (4) 67% of 60° internally rotated view, and (5) 98% of 90° internally rotated view. Inter- and intra-observer concordance was within 5% error. As the angle of internal rotation approached 90° the deltoid tuberosity became less prominent and in the 90° projection it was not seen in any of the bones.

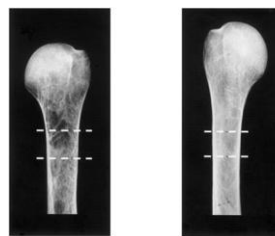
**DISCUSSION:** Our results clearly show that regardless of the radiographic view the deltoid tuberosity could not be seen in many cases. This was especially true in the internal rotation view that would most likely mirror that of a typically sized patient in a sling (i.e., 60° internal rotation). Mack et al. (1989) [9] reported similar results also showing that the deltoid tuberosity cannot be identified in many cases. They evaluated clinical radiographs of the proximal humerus of 66 adults spanning from 20 years of age (estimated) to 94 years (mean: 44 years; males: n=32; females: n=34). They examined what appeared to be AP projections (similar to our “epicondyles flat” and 30° rotated views) and found that only 29% of patients <35 years of age showed any radiographic evidence of the deltoid tuberosity. The percentage of radiographs that did not show the greater tuberosity increased to 48% in the 36-64 year-old age group and increased to 46% in those ≥65 years old. In view of our data and those of Mack et al.[9] it is interesting that Spross et al. [4] did not report the inability to identify the proximal aspect of the deltoid tuberosity in the internal rotation radiographs of their 71 patients (31 scheduled for elective surgery and 40 who had surgery for ipsilateral proximal humerus). In Spross et al. the radiographs of the non-fracture group were evaluated only by the principal investigator/first author (Spross) and the radiographs of the fractured humerus were evaluated by Spross and author EB. Observer bias may have been high because the principal investigator/lead author was likely not blinded to the hypothesis of the study. We have recently described a more reliable and accurate method for making CI and mean combined cortical thickness measurements on clinical radiographs of the proximal humerus. This method, which does not rely on the unreliable deltoid tuberosity, is based on a circle is digitally fit to the articular surface of the humeral head. The locations for these measurements are then made at 10mm increments below the transverse tangent of this humeral head circle [3]. But additional studies are needed to develop reliable methods that can be employed in cases where the proximal humerus is fractured.

**SIGNIFICANCE:** Use of the deltoid tuberosity index (DTI) is problematic for basic and applied applications because it is based on an unreliable landmark (the proximal aspect of the deltoid tuberosity) for its measurement. Other methods should be used that are more reliable and accurate.

**REFERENCES:** [1] Tingart et al. 2003 JBJS 85:611-; [2] Mather et al. 2013 JSES 22:732-; [3] Skedros et al. 2015 J Orthop Res (in press); [4] Spross et al. 2015 Clin Orthop Rel Res 473:3038-; [5] Nho et al. 2007 JBJS 89:44-; [6] Tillett et al. 1993 J Shoulder Elbow Surg 2:255-; [7] Pearl and Volk 1995 J Shoulder Elbow Surg 4:286-; [8] Skedros et al. 2014 Biores Open Access 3:250-; [9] Mack et al. (1989) Nucl. Med. Biol. 16: 469-.

TRIAL	FLAT			30°			60°			90°		
	View	Observer	DTI	View	Observer	DTI	View	Observer	DTI	View	Observer	DTI
A	104.8	109.8	105.4	96.9	97.3	95.9	100	91.4	98.3	106.4	103.9	0
B	138.8	131	130.6	130.3	122.2	131.6	0	0	0	0	0	0
C	144.8	140	143.8	0	0	0	0	0	0	0	0	0
D	131.7	136.3	143.8	118.4	117.7	123.4	0	0	0	0	0	0
E	118.6	116.9	118.6	105.9	115.2	120.6	108.9	114.2	120.6	0	0	0
F	137	133.8	133.8	144.4	146.1	149.1	136.9	127.1	131.5	0	0	0
G	131.4	139.4	139.8	122.3	123.6	129.5	0	0	0	105.3	102	0
H	129.2	134.4	133.8	0	0	0	0	0	0	0	0	0
I	96.7	101.1	98.1	90.1	90.6	93.5	92.4	93.4	94.8	0	0	0
J	94.8	101.4	96.5	81	81.2	84.8	81.7	86.4	86.5	0	0	0
K	139.8	139.8	139.8	0	0	0	0	0	0	0	0	0
L	137.2	131	139.2	118.3	126.4	127.3	119.3	120.3	121.2	110.2	102	0
M	0	116.8	116.8	96.3	96.3	96.3	96.3	96.3	96.3	96.3	115.2	106.1
N	126.1	113.6	113.3	108.4	110.3	110.3	99.3	109.2	110	0	0	0
O	124.4	127.2	127.2	112.4	115.5	116.7	112.4	115.5	116.7	113.8	114.4	117.2
P	115.9	119.2	109.7	0	0	0	105.8	103.8	107	0	0	0
Q	0	0	0	0	0	0	0	0	0	0	0	0
R	118.9	120.1	119.1	115.3	116.1	117.2	112.7	113.3	115.9	112	112	0
S	127	114.5	114.5	107.6	118.5	120.2	94.9	101.9	96.4	92.7	92.1	93.8
T	0	121.9	0	0	113.1	0	0	0	0	110	113.1	0
# of Bones Measured	121	19	18	12	18	16	10	16	10	6	8	6
%	60.5	9.5	9	6	9	8	5	8	5	3	4	3
Standard Deviation of Observers	13	2	2	1	1	1	1	1	1	1	1	1
Standard Deviation of Observers	81.7	76.7	76.7	76.7	76.7	76.7	76.7	76.7	76.7	76.7	76.7	76.7

Figure 1. (middle two images)



Radiographic images from Tingart et al (2003) [1].

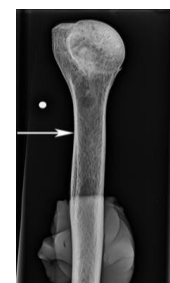

Figure 2. (far right image) The 5.0mm radio-opaque (white) circle indicates the lateral side of the humerus. The arrow indicates where the rater marked the proximal location of the deltoid tuberosity according to Spross et al. (2015) definition.